

CHARALAMPOS GRIGORIADIS¹

ALIKI TYMPA²

MARIA CREATSA¹

PANAGIOTIS BAKAS¹

ANGELOS LIAPIS¹

AGATHI KONDI-PAFITI³

GEORGIOS CREATSAS¹

Hofbauer cells morphology and density in placentas from normal and pathological gestations

Morfologia e densidade das células de Hofbauer em placentas de gestações normais e patológicas

Original Article

Keywords

Hofbauer cells
Placenta/cytology
Immunohistochemistry
Fetal growth retardation
Diabetes, gestational

Palavras-chave

Células de Hofbauer
Placenta/citologia
Imunohistoquímica
Retardo do crescimento fetal
Diabetes gestacional

Abstract

PURPOSE: In placentas from uncomplicated pregnancies, Hofbauer cells either disappear or become scanty after the fourth to fifth month of gestation. Immunohistochemistry though, reveals that a high percentage of stromal cells belong to Hofbauer cells. The aim of this study was to investigate the changes in morphology and density of Hofbauer cells in placentas from normal and pathological pregnancies. **METHODS:** Seventy placentas were examined: 16 specimens from normal term pregnancies, 10 from first trimester's miscarriages, 26 from cases diagnosed with chromosomal abnormality of the fetus, and placental tissue specimens complicated with intrauterine growth restriction (eight) or gestational diabetes mellitus (10). A histological study of hematoxylin-eosin (HE) sections was performed and immunohistochemical study was performed using the markers: CD 68, Lysozyme, A1 Antichymotrypsine, CK-7, vimentin, and Ki-67. **RESULTS:** In normal term pregnancies, HE study revealed Hofbauer cells in 37.5% of cases while immunohistochemistry revealed in 87.5% of cases. In first trimester's miscarriages and in cases with prenatal diagnosis of fetal chromosomal abnormalities, both basic and immunohistochemical study were positive for Hofbauer cells. In pregnancies complicated with intrauterine growth restriction or gestational diabetes mellitus, a positive immunoreaction was observed in 100 and 70% of cases, respectively. **CONCLUSIONS:** Hofbauer cells are present in placental villi during pregnancy, but with progressively reducing density. The most specific marker for their detection seems to be A1 Antichymotrypsine. It is remarkable that no mitotic activity of Hofbauer cells was noticed in our study, as the marker of cellular multiplication Ki-67 was negative in all examined specimens.

Resumo

OBJETIVO: Em placentas de gestações sem complicações, as células de Hofbauer desaparecem ou se tornam raras após o quarto ou quinto mês de gestação. Entretanto, a imunohistoquímica revela que uma alta porcentagem de células estromais pertencem às células de Hofbauer. O objetivo do presente estudo foi investigar as alterações da morfologia e densidade das células de Hofbauer em placentas de gestações normais e patológicas. **MÉTODOS:** Foram examinadas 70 placentas: 16 provenientes de gestações normais a termo, 10 de abortos espontâneos no primeiro trimestre, 26 de casos diagnosticados como anormalidade cromossômica do feto, e amostras de tecido placentário com complicações causadas pela restrição de crescimento intrauterino (8) ou pelo diabetes mellitus gestacional (10). Cortes corados com hematoxilina-eosina (HE) foram submetidos a estudo histológico e imunohistoquímico utilizando-se os seguintes marcadores: CD 68, lisozima, antiqumotripsina A1, CK-7, vimentina, e Ki-67. **RESULTADOS:** Em gestações normais a termo, o estudo HE revelou células de Hofbauer em 37,5% dos casos, enquanto a imunohistoquímica as revelou em 87,5% dos casos. Em abortos do primeiro trimestre e em casos de diagnóstico prenatal de anormalidades cromossômicas fetais, tanto o estudo básico como o estudo imunohistoquímico foram positivos para células de Hofbauer. Em gestações complicadas pela restrição de crescimento intrauterino ou pelo diabetes mellitus gestacional, imunoreação positiva foi observada respectivamente em 100 e 70% dos casos. **CONCLUSÕES:** As células de Hofbauer estão presentes nos vilos placentários durante a gestação, embora com densidade progressivamente reduzida. O marcador mais específico para sua detecção parece ser a antiqumotripsina A1. Vale salientar que atividade mitótica de células de Hofbauer não foi detectada em nosso estudo, uma vez que o marcador de multiplicação celular Ki-67 foi negativo em todas as amostras examinadas.

Correspondence

Charalampos Grigoriadis
2nd Department of Obstetrics and Gynecology, Aretaieion University
Hospital, 76 Vas.Sofias Avenue
11528
Athens, Greece

Received

09/02/2013

Accepted with modifications

09/25/2013

Study carried out at the University of Athens, Medical School, Aretaieion Hospital, Greece

¹2nd Department of Obstetrics and Gynecology, University of Athens, Medical School, Aretaieion Hospital, Greece.

²1st Department of Anesthesiology, University of Athens, Medical School, Aretaieion Hospital, Greece.

³Pathology Laboratory, University of Athens, Medical School, Aretaieion Hospital, Greece.

Conflict of interests: none.

Introduction

From the middle of the 19th century, several studies have reported the presence of large cells in the stroma of chorionic villi of the human placenta. The precise location of these cells in the villous stroma was first described by Kastschenko in 1885, while Virchow, and later Chaletzky and Neumann first commented on the association of hydatidiform mole with large isolated cells having clear cytoplasm. This finding led to the term Chaletzky-Neumann cells, used in the past by several investigators. However, Hofbauer¹ was the first who gave a comprehensive morphological and functional description of these cells in normal villi at the beginning of the 20th century, and the term Hofbauer cell (HBCs) was then widely accepted in the literature.

HBCs have been described as frequent, pleomorphic cells of the villous stroma with round, fusiform, or stellate appearance. Their size depends on the length of their processes. The cells vary from 10 to 30 μm in diameter. Early studies had already found that the most striking aspects of HBCs are their highly vacuolated appearance and their granulated cytoplasm². Later investigations have pointed out that HBCs are characterized by numerous membrane-bound, electron-lucent vacuoles of different sizes, possessing amorphous material of varying density, dense granules (presumably lysosomes), and short profiles of endoplasmic reticulum^{1,3-7}.

Several theories have been reported trying to explain the origin of the HBCs. These include those proposed by Chaletzky who derived them from cells of maternal decidua; those by Neumann who considered them to be derivatives of the syncytium and an expression of malignancy; and other which supported that these cells could be derivatives of endothelial cells¹. A very important finding concerning the origin of HBCs was Wynn's observation, based on sex chromatin staining, that these are fetal cells⁸. So, most investigators now believe that HBCs are of chorionic mesenchymal origin. They can be recognized in placental villi at a very early stage of development (after the 18th day of gestation). It has been supported that in placentas from uncomplicated pregnancies, HBCs either disappear or become scanty after the fourth to fifth month of gestation. On the other hand, in cases of pathological placentas due to intrauterine growth restriction (IUGR) or gestational diabetes mellitus their density seems to be increased^{4,6,9}. However, electron microscopy studies and immunohistochemistry demonstrated their presence throughout normal uncomplicated pregnancy as well, until term, and not only in immature villi of the center of the placentone.

As far as their function is concerned, HBCs are capable of both immune and non-immune phagocytosis, they can trap maternal antibodies crossing over into the

placental tissues and are probably an important source of cytokines, prostaglandins, and thromboxane within the placenta¹⁰⁻¹². The high levels of phagocytosis in HBCs confirm their macrophage function¹³. Other suggested hypothetical functions such as maintenance of placental water balance, involvement in transport mechanisms, a possible endocrine function, and a role in the control of vasculogenesis remain controversial^{1,14}. Most recently it has been reported that HBCs express sprouty proteins and therefore play an important role in placental development by modulating branching of the villous tree¹⁵.

The aim of this study was to investigate the differences in morphology and density of HBCs between placentas from normal and pathological pregnancies, as well as between placentas from term gestations and first trimester miscarriages. Additionally, the function of these cells, their macrophage character and mitotic potential were examined.

Methods

This was a research immunopathological study, approved by the Institutional Research Committee, which was organized in Aretaieion University Hospital in Athens. Multiple sections from 70 specimens of whole placental tissue were examined: 16 specimens were received from normal term pregnancies; 10 from first trimester's miscarriages; 26 from pregnancies between the 13th and 23rd week of gestation, diagnosed with chromosomal abnormality of the fetus, that were led to termination; eight from pregnancies between the 32nd and 38th week of gestation, complicated with IUGR; and, finally, 10 specimens were received from pregnancies between the 32nd and 38th week of gestation, associated with gestational diabetes mellitus.

A histological study of hematoxylin-eosin (HE) sections from formalin-fixed and paraffin-embedded placental tissues was performed for semi-quantitative determination of HBCs concentration per villus and their basic morphology. At least 50 villi per case were examined under high-power field ($\times 400$) observation. The density of HBCs per villus was determined by two independent observers and subsequently graded as 'focal' (+) (1-3 HBCs/villus), 'intermediate' (++) (3-6 HBCs/villus), or 'diffuse' (+++) (>6 HBCs/villus).

Additional sections of each case were obtained for immunohistochemical investigation by Automated Ventana Immunostainer. The slides were incubated with CD 68 (Cell Marque), as monocyte-macrophage marker; A1 Antichymotrypsine (Cell Marque), as macrophage marker; Lysozyme (Cell Marque), as histiocyte marker; Ki-67 (Novocastra), as marker of cellular proliferation; Cytokeratin-7 (CK-7; Dako-Accurate Chemical and Scientific Corporation, USA), as marker of epithelial-glandular differentiation, and Vimentin (Monosan), as marker of mesenchymatic differentiation.

Results

Group A. Placentas from normal term uncomplicated pregnancies — 16 cases

A focal presence of HBCs in mainly intermediate villi in 6/16 (37.5%) placental specimens of normal term gestations was observed during the basic HE (Table 1). The rest 10 placental specimens were negative for HBCs presence at the basic study. However, additional immunohistochemical study revealed, via the macrophage marker A1 Antichymotrypsine, focal density of HBCs in 14/16 (87.5%) specimens, while positive immunostain was noticed for the marker CD 68 as well in half of the cases.

Their morphological analysis showed cells with oviform shape, round nuclei, and granulated cytoplasm (Figure 1). No mitotic activity was observed and the marker of cellular proliferation Ki-67 was positive in less than 5% of all examined specimens.

Group B. Placentas from first trimester's miscarriages — 10 cases

Basic HE study was positive for HBCs presence in all cases (10/10). Diffuse density of HBCs was observed in 10% of the cases, intermediate in 50% of the cases, while focal presence of HBCs was seen in the rest 40% of first trimester's placentas during HE study (Figure 2). Immunohistochemistry was positive for presence of HBCs in these placental tissue specimens too, as markers A1 Antichymotrypsine, CD 68, and Lysozyme had positive immunostain reaction in 100%, 80%, and 50% of examined specimens, respectively (Table 2). No positive immunostain reaction was noticed after the use of markers Vimentin, CK-7, or Ki-67. According to their morphology, HBCs in these early weeks of gestation were recognized having a round shape with thin-colored nuclei and coccophile cytoplasm.

Group C. Placentas from pregnancies between 13th and 23rd week of gestation, diagnosed with chromosomal abnormality of the fetus that were led to termination — 26 cases

Basic HE study was positive for HBCs presence in all cases (26/26). Diffuse density of HBCs was observed in 15.4% of the cases, intermediate in 26.9%, while focal presence of HBCs was seen in 57.7% of the cases. Immunohistochemistry was positive for presence of HBCs in these placental tissue specimens too, as markers A1 Antichymotrypsine showed positive immunostain in all the cases. Positive immunostain reaction was also observed using the markers CD 68 and Lysozyme in 88.5% and 50% of examined specimens, respectively (Figure 3). No positive immunostain reaction was noticed after the use of markers Vimentin, CK-7, or Ki-67 (<5%). As to

Table 1. Results of basic hematoxylin-eosin study

	HBCs	Presence	Density
	No	%	%
Normal term uncomplicated pregnancies	6/16	37.5	F100
First trimester's miscarriages	10/10	100	D10, IN50, F40
Chromosomal abnormality	26/26	100	D15, IN27, F58
IUGR	5/8	62.5	F100
Gestational diabetes mellitus	7/10	70	IN14, F86

D: diffuse density of HBC; F: focal density; IN: intermediate density; HBC: Hofbauer cell.

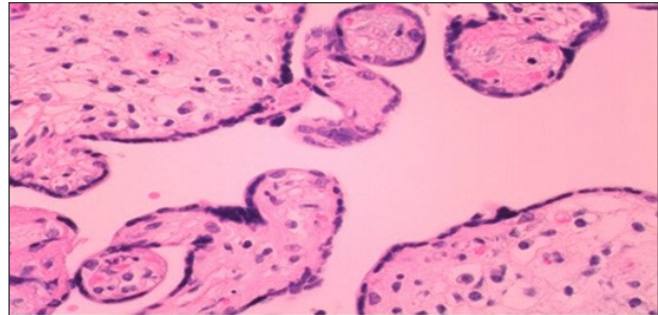


Figure 1. Histological section of mature villi with rare isolated Hofbauer cells located by stromal channels (HE ×120)

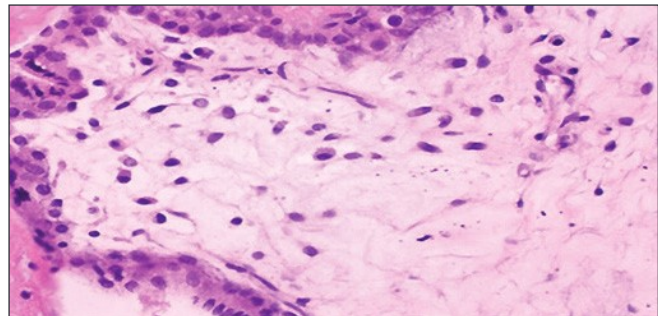


Figure 2. In a higher magnification of a histological section of first trimester's villi with hydropic stroma numerous Hofbauer cells are observed (HE ×400)

their morphology, no remarkable differences were noticed between HBCs from placentas with chromosomal abnormalities and HBCs from first trimester's placental specimens. HBCs in both categories were recognized with a round shape, thin-colored nuclei without mitoses, and coccophile cytoplasm.

Group D. Placentas from pregnancies between the 32nd and 38th week of gestation, complicated with IUGR — eight cases

A focal presence of HBCs in 5/8 (62.5%) placental specimens of pregnancies complicated with IUGR was observed during the basic HE study. The rest three placental specimens were negative for HBCs presence at the basic

Table 2. Results of immunohistochemical study

	CD 68		A1 Antichymotrypsine		Lysozyme	
	HBCs presence	Density	HBCs presence	Density	HBCs presence	Density
	%	%	%	%	%	%
Normal term uncomplicated pregnancies	50	F100	87.5	F100	12.5	F100
First trimester's miscarriages	80	F100	100	F100	50	F100
Chromosomal abnormality	88.4	D27, IN23, F50	100	IN15, F85	50	F100
IUGR	37.5	F100	100	F100	12.5	F100
Gestational diabetes mellitus	40	F100	70	F100	30	F100

D: diffuse density of HBCs; F: focal density; IN: intermediate density; HBC: Hofbauer cell.

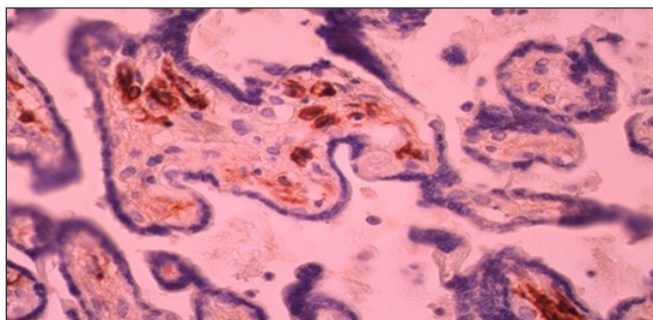


Figure 3. Intermediate villous from placenta with chromosomal abnormality of the fetus. Diffuse concentration of Hofbauer cells, stained with the marker CD 68 (CD 68x120)

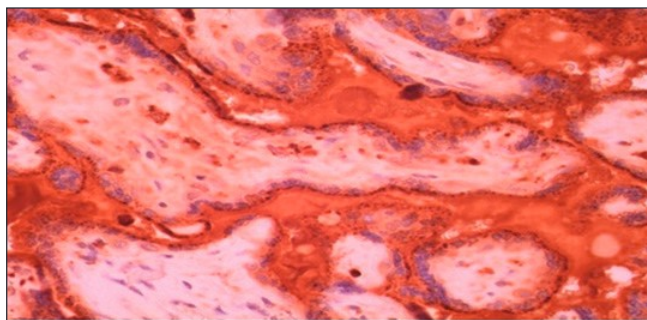


Figure 4. Villi from placenta of IUGR pregnancy. Focal concentration of Hofbauer cells stained with A1 Antichymotrypsine. Extensive areas of fibrin between the villi, showing the decreasing function of the IUGR placenta (A1 Antichymotrypsine x120)

study. However, additional immunohistochemical study revealed, via the macrophage marker A1 Antichymotrypsine (Figure 4), focal presence of HBCs in all specimens (8/8) while positive immunostain was noticed for the marker CD 68 as well in 37.5% of the cases. Negative results were noticed in all cases after the use of markers such as Vimentin, CK-7, and Ki-67 (<5%). The morphological characteristics of HBCs from IUGR pregnancies did not present significant differences from HBCs of the same gestational age normal placentas.

Group E. Placentas from pregnancies between the 32nd and 38th week of gestation complicated with gestational diabetes mellitus — 10 cases

Both basic HE study and immunohistochemistry, using the macrophage marker A1 Antichymotrypsine (Figure 5), revealed presence of H.c in 7/10 (70%) placental specimens from pregnancies complicated with gestational diabetes mellitus. Immunohistochemistry failed to show HBCs presence in cases in which basic study was negative. In the vast majority of cases, the density of HBCs was characterized as focal (6/7, 85.7%), while only in one case it was intermediate (1/6, 14.2%). Positive immunostain reaction was observed using the marker CD 68 in 40% of the cases. No positive reaction was noticed after the use of Vimentin, CK-7, or Ki-67 (<5%). The morphological characteristics of HBCs from

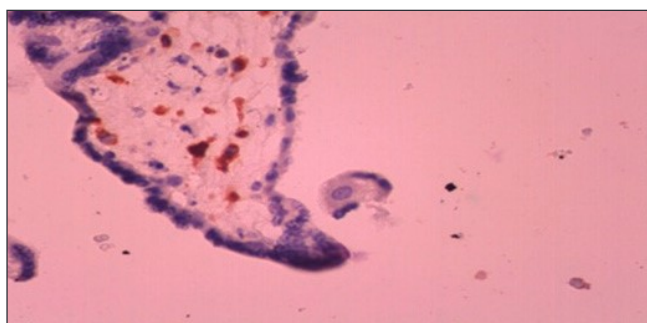


Figure 5. Hofbauer cells in placenta from pregnancy complicated with gestational diabetes mellitus (A1 Antichymotrypsine x120)

pregnancies complicated with maternal diabetes mellitus did not present significant differences compared with HBCs of the same gestational age normal placentas.

Discussion

The findings of our report are in agreement with recently published reports which support that HBCs are macrophages of fetal origin and can be found in human placental villi, playing a potential role in villitis of unknown etiology^{13,16}. The positive immunostain reaction of these cells after incubation with macrophage markers was characteristic. Antichymotrypsine (A1) was recognized as

the most specific marker for HBCs determination, as it revealed HBC presence even in cases in which basic HE study was negative. Positive immunostain reaction was also observed in a significant percentage of cases, using the monocyte-macrophage marker CD 68, while a poor response was noticed after incubation with Lysozyme. On the other hand, HBCs did not show any reaction after incubation with markers of glandular-epithelial (CK-7) or mesenchymatic differentiation (Vimentin).

Several studies support an important role of A1 Antichymotrypsine in inhibition of natural killing and antibody-dependent cell-mediated cytotoxicity¹⁷. If A1 Antichymotrypsine functions in this capacity in the vicinity of the placenta this could provide a mechanism for preventing the two modes of the cellular immune response that would otherwise become engaged during an allogenic recognition reaction¹⁸. So, the extensive distribution of A1 Antichymotrypsine within placental HBCs may have particular relevance to the lack of maternal response toward the fetus. Since the location and repertory of HBCs secreted products makes them ideal candidates for a second line of defense against infection, their possible 'immature macrophage' status, because of their poor response after incubation with Lysozyme, but with a full phagocytosis function, leads to further investigations concerning their potential role in the pathogenesis of placental infection¹³⁻¹⁶.

It becomes important to examine whether the poor immunostain reaction for Lysozyme is characteristic of HBCs, or whether its synthesis and secretion can be induced by infection, particularly in bacterial infection where this enzyme would have an effective bactericidal action¹⁹. Thus, macrophages that are immature or lack the ability to be activated, such as the HBCs, may play an important role in the transmission of organisms capable to infect the placenta (like bacteria, chlamydia, toxoplasma, cytomegalovirus), as they have full phagocytosis capacity but may lack substances, such as lysozyme and peroxidase, necessary to destroy or inactivate the infectious agent. Additionally, the fact that these specialized placental macrophages express receptors, such as PC-SIGN and L-SIGN, sheds light to HIV-1 vertical transmission²⁰.

The marker of cellular proliferation Ki-67 was negative in all examined placental specimens. This finding, in correlation with the fact that no mitoses were observed during the morphological study of HBCs nuclei, leads to the conclusion that these cells do not have mitotic activity.

According to the literature, HBCs originate from mesenchymal cells during the early stages of pregnancy, before the fetal circulation is established. Later, once fetal circulation is established, HBCs may additionally originate from fetal bone marrow-derived monocytes, as macrophages in other organs do. Finally, it has been

proposed that HBCs may have different origins throughout pregnancy and that may represent a heterogeneous group of cells⁶. These data are related to in vivo and in vitro observations, showing that HBCs can undergo mitotic division⁶. Their potential mitotic activity could mean that HBCs may be, in part, an independent self-replicating cellular population, allowing rapid increase in concentration when required by the local microenvironment. However, our results, employing the marker Ki-67, do not agree with the previous mentioned research studies, as we found that HBCs do not have proliferative activity.

Our study shows that HBCs are easily detected, with both basic HE study and immunohistochemistry, in the intermediate villi of first trimester's gestations. Their density in these cases could be diffuse, associated with a possible role in the control of villous development by remodeling of the villous core by stimulating or inhibiting the proliferation of other mesenchymal cells, controlling villous angiogenesis by secreting angiogenetic cytokines, or controlling trophoblast turnover by inducing trophoblast apoptosis and syncytial fusion.

In both, first trimester's miscarriages as well as in termination of pregnancy because of prenatal diagnosis of fetal chromosomal abnormality between the 13th and 23rd week of gestation, basic HE study and immunohistochemistry, via A1 Antichymotrypsine, was positive for HBCs presence in all examined placental specimens. The higher density of HBCs per villous was also observed in these two groups, in comparison with the other three examined categories (normal term placentas, placentas from pregnancies complicated with IUGR or gestational diabetes mellitus).

Immunohistochemistry revealed, by the use of marker A1 Antichymotrypsine, the presence of HBCs in 87.5% of uncomplicated term pregnancies. However, HBCs' density was characterized focal in all cases, as no more than three cells per villous were found. So, there is a significant difference in HBCs' density between early and term gestations. The reduction of HBCs in number as pregnancy progresses possibly occurs because the cells are compressed and masked by the condensation of the villous stroma during placental maturation. Additionally, in placentas from pregnancies complicated with pre-eclampsia, a reduced HBCs' density has been found via immunohistochemistry, using macrophage markers folate receptor (FR)- β , CD 163, and CD 68²¹. On the other hand, in cases of miscarriage, chromosomal abnormalities, or maternal diabetes as well as in other pathologic conditions such as Rhesus incompatibility, these macrophages are more easily identifiable because of the edematous morphology of the villi which can unmask numerous HBCs.

Even if the density of HBCs in placentas from normal term gestations was found focal, these cells were present in

the vast majority of cases, as immunohistochemistry was positive in 87.5% of the examined specimens. So, our study is in agreement with recently published reports which support that HBCs are present in placental villi throughout pregnancy, but with progressively reducing concentration. The significant difference in recognition of HBCs presence in normal term placentas between basic HE study (37.5%) and immunohistochemistry (87.5%) could be explained from the difficulty of HE study to morphologically identify HBCs in term placentas due to their compression. So, the role of immunohistochemistry in normal term placentas is important in order to recognize these cells.

Additionally, the characteristics of HBCs were analyzed in cases of pregnancy pathologies, such as in IUGR gestations and in cases diagnosed with maternal diabetes mellitus. The marker A1 Antichymotrypsine revealed

HBCs presence in all cases (100%) of IUGR pregnancies and in 70% of placental specimens from pregnancies complicated with gestational diabetes mellitus. Recent literature suggests that diabetes/hyperglycemia affect the anti-inflammatory profile of HBCs by stimulating these cells to acquire an inflammatory profile leading to adverse consequences for the fetal-placental-maternal axis²².

In conclusion, HBCs are present in placental villi of both normal and pathological pregnancies. Remarkable is their presence in all specimens from IUGR pregnancies, but with focal concentration.

There were also significant morphological changes observed, with the first trimester's round shape of the cells that had coccophile cytoplasm to be replaced, with the progress of gestation, by an oviform cellular shape with granulated cytoplasm in term placentas.

References

- Hofbauer J. The function of the Hofbauer cells of the chorionic villus, particularly in relation to acute infection and syphilis. *Am J Obstet Gynecol.* 1925;10(1):1-14.
- Enders AC, King BF. The cytology of Hofbauer cells. *Anat Rec.* 1970;167(2):231-6.
- Vinnars MT, Rindsjo E, Ghazi S, Sundberg A, Papadogiannakis N. The number of CD68(+) (Hofbauer) cells is decreased in placentas with chorioamnionitis and with advancing gestational age. *Pediatr Dev Pathol.* 2010;13(4):300-4.
- Demir R, Erben T. Some new findings about Hofbauer cells in the chorionic villi of the human placenta. *Acta Anat (Basel).* 1984;119(1):18-26.
- Castellucci M, Zaccheo D, Pescetto G. A three-dimensional study of the normal human placenta villous core. I. The Hofbauer cells. *Cell Tissue Res.* 1980;210(2):235-47.
- Kondi-Pafiti A, Grigoriadis C, Samiotaki D, Filippidou-Giannopoulou A, Kleanthis C, Hassiakos D. Immunohistochemical study of inhibin A and B expression in placentas from normal and pathological gestations. *Clin Exp Obstet Gynecol.* 2013;40(1):109-12.
- King BF. Ultrastructural differentiation of stromal and vascular components in early macaque placental villi. *Am J Anat.* 1987;178(1):30-44.
- Wynn RM. Derivation and ultrastructure of the so-called Hofbauer cell. *Am J Obstet Gynecol.* 1967;97(2):235-48.
- Martinoli C, Castellucci M, Zaccheo D, Kaufmann P. Scanning electron microscopy of stromal cells of human placental villi throughout pregnancy. *Cell Tissue Res.* 1984;235(3):647-55.
- Hauguel-de Mouzon S, Guerre-Millo M. The placenta cytokine network and inflammatory signals. *Placenta.* 2006;27(8):794-8.
- Wood GW, King GR Jr. Trapping antigen-antibody complexes within the human placenta. *Cell Immunol.* 1982;69(2):347-62.
- Wetzka B, Clark DE, Charnock-Jones DS, Zahradnik HP, Smith SK. Isolation of macrophages (Hofbauer cells) from human term placenta and their prostaglandin E2 and thromboxane production. *Hum Reprod.* 1997;12(4):847-52.
- Tang Z, Tadesse S, Norwitz E, Mor G, Abrahams VM, Guller S. Isolation of Hofbauer cells from human term placentas with high yield and purity. *Am J Reprod Immunol.* 2011;66(4):336-48.
- Seval Y, Korgun ET, Demir R. Hofbauer cells in early human placenta: possible implications in vasculogenesis and angiogenesis. *Placenta.* 2007;28(8-9):841-5.
- Anteby EY, Natanson-Yaron S, Greenfield C, Goldman-Wohl D, Haimov-Kochman R, Holzer H, et al. Human placental Hofbauer cells express sprouty proteins: a possible modulating mechanism of villous branching. *Placenta.* 2005;26(6):476-83.
- Tamblyn JA, Lissauer DM, Powell R, Cox P, Kilby MD. The immunological basis of villitis of unknown etiology – Review. *Placenta.* 2013;34(10):846-55.
- Gravagna P, Gianazza E, Arnaud P, Neels M, Ades EW. Modulation of the immune response by plasma protease inhibitors. III. Alpha 1-antichymotrypsin inhibits human natural killing and antibody-dependent cell-mediated cytotoxicity. *J Reticuloendothel Soc.* 1982;32(2):125-30.
- Braunhut SJ, Blanc WA, Ramanarayanan M, Marboe C, Mesa-Tejada R. Immunocytochemical localization of lysozyme and alpha-1-antichymotrypsin in the term human placenta: an attempt to characterize the Hofbauer cell. *J Histochem Cytochem.* 1984;32(11):1204-10.
- Gajewska E, Woyton J. Lysozyme activity in parturient women and their newborns in cases of infection. *Arch Immunol Ther Exp (Warsz).* 1978;26(1-6):665-70.
- da Silva RC, Segat L, Zanin V, Arraes LC, Crovella S. Polymorphisms in DC-SIGN and L-SIGN genes are associated with HIV-1 vertical transmission in a Northeastern Brazilian population. *Hum Immunol.* 2012;73(11):1159-65.
- Tang Z, Buhimschi IA, Buhimschi CS, Tadesse S, Norwitz E, Niven-Fairchild T, et al. Decreased levels of folate receptor-β and reduced numbers of fetal macrophages (Hofbauer cells) in placentas from pregnancies with severe preeclampsia. *Am J Reprod Immunol.* 2013;70(2):104-15.
- Sisino G, Bouckenoghe T, Aurientis S, Fontaine P, Storme L, Vambergue A. Diabetes during pregnancy influences Hofbauer cells, a subtype of placental macrophages, to acquire a pro-inflammatory phenotype. *Biochim Biophys Acta.* 2013;1832(12):1959-68.